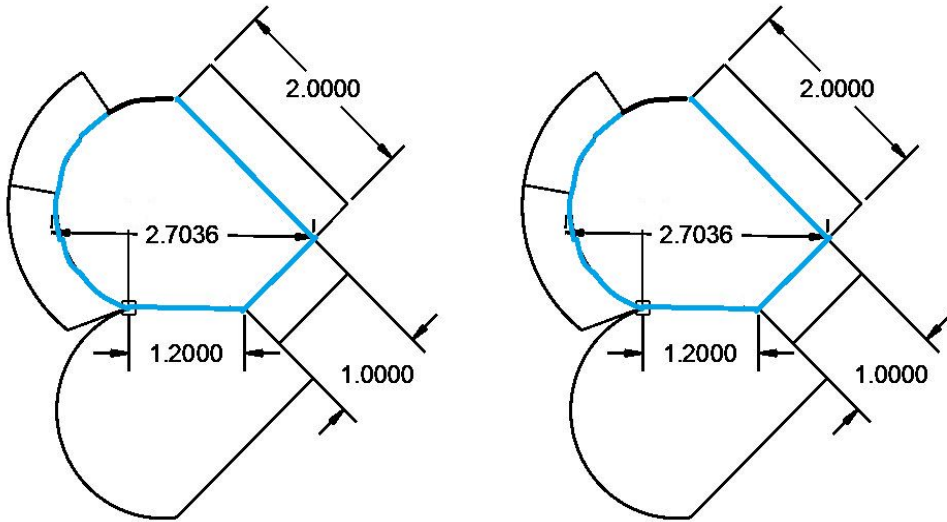
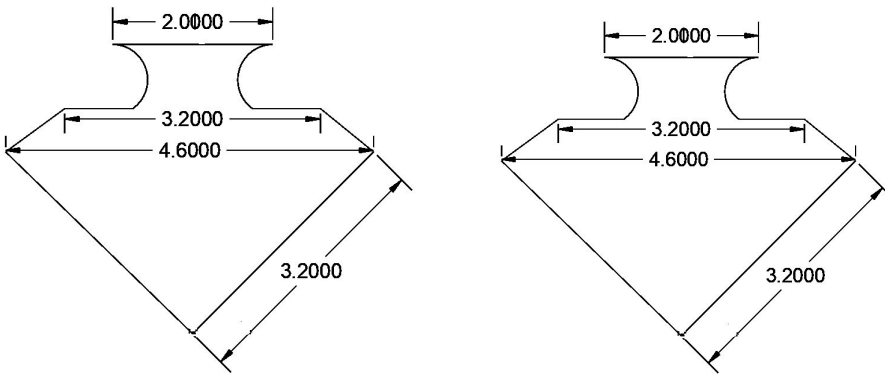


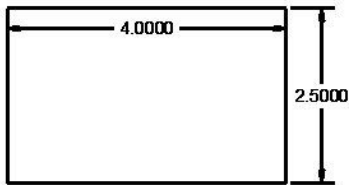
Atriums (fold on blue)



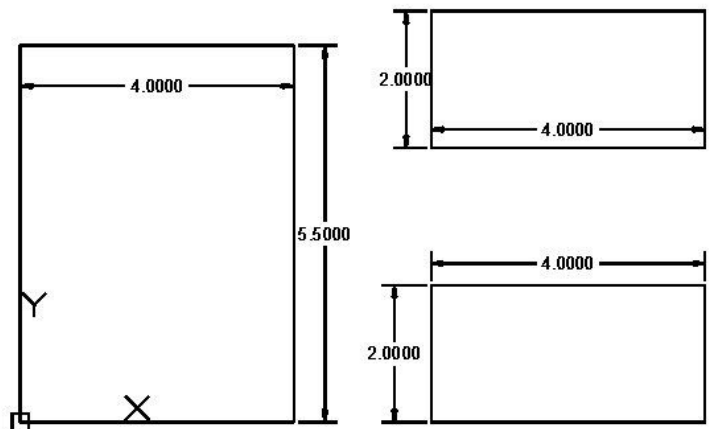
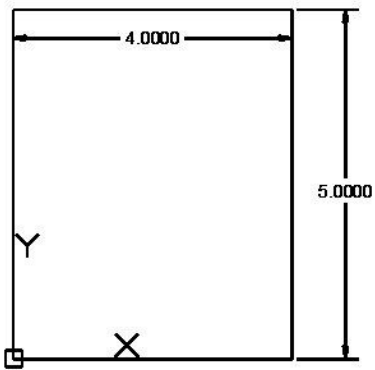
Ventricles (left one should be a little bigger)



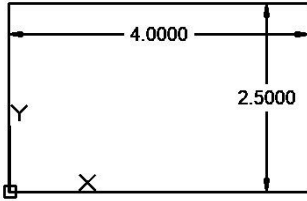
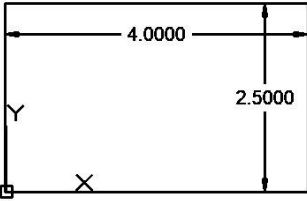
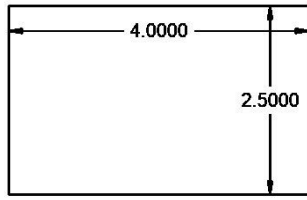
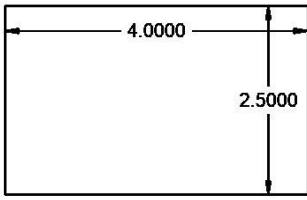
Pulmonary artery (roll along 4cm side)



aorta (roll along 4cm side)



Inferior & superior vena cava + pulmonary vein



Tricuspid & mitral valve

